

MORPHOLOGICAL, IMMUNOPHENOTYPIC AND CLINICAL CHARACTERISTICS OF DOGS WITH LYMPHOCYTIC – PLASMACYTIC DUODENITIS

DORĐEVIĆ MILENA, KRSTIĆ V, KRSTIĆ N, VASILJEVIĆ MAJA, ILIĆ V, VUČIĆEVIĆ IVANA
and ALEKSIĆ-KOVAČEVIĆ SANJA

University of Belgrade, Faculty of Veterinary Medicine, Belgrade, Serbia

(Received 26th December 2011)

The most important morphological feature of the immune response in lymphocytic-plasmacytic duodenitis (LPD) in dogs is the presence of a mononuclear infiltrate in the duodenal mucosa. The etiopathogenesis of this disease is still unknown, nor are known all the immunophenotypic characteristics of the infiltrate cells, which would be of help in the elucidation of the pathogenesis of LPD.

The study involved 60 adult dogs of different breeds and both sexes: 54 dogs with symptoms of diarrhea and vomiting that lasted longer than three weeks and six clinically healthy dogs that served as controls. Hematological and biochemical analysis of blood, radiology, ultrasound and endoscopic diagnosis were carried out. Samples of duodenal mucosal biopsies were examined by histopathological and immunohistochemical methods.

During endoscopic examination, duodenal wall thickening, mucosal edema and hyperemia were observed in 46 dogs. Microscopic studies showed on the epithelial cells of the duodenum degenerative changes, and sometimes desquamation. Most of the intestinal crypts were dilated, irregularly shaped and filled with detritus. On immunohistochemical examination of samples of the duodenum in a number of dogs with LPD a predominant expression of CD3 + T lymphocytes was observed.

Key words: dog, duodenum, endoscopy, histopathology, LPD

INTRODUCTION

Lymphocytic – plasmacytic duodenitis (LPD) in dogs is a form of chronic inflammatory disease of the duodenum accompanied by nonspecific clinical symptoms. The most important morphological characteristic of the immune response in this type of inflammatory bowel disease is the finding of mononuclear infiltrates in the mucosa of the duodenum. To date, the etiopathogenesis of this disease in all dogs is not clear nor are the immunophenotypic characteristics of all cells in the infiltrate, which would be relevant for better understanding of the

etiopathogenesis of LPD (Whitley *et al.*, 2011; Washabau *et al.*, 2010; Kobayashi *et al.*; 2006).

The description of the inflammatory changes in biopsy samples obtained by endoscopy of duodenal dogs' mucosa, is an important step in the diagnosis and treatment of patients with LPD (Simpson *et al.*, 2011; Craven *et al.*, 2004). For many years, there were no standard criteria for the interpretation of histopathological findings in dogs with LPD. Comparison of results is difficult due to different criteria that were used in the diagnosis (Day *et al.*, 2008).

The World Association of Small Animal Veterinary Practice (The World Small Animal Veterinary Association - WSAVA) realized the importance of having standardized criteria for the assessment of morphological changes that are observed in the intestinal mucosal tissues in tested dogs with inflammatory bowel disease, including LPD dogs, thus, proposing standardization (WSAVA International Gastrointestinal Standardization Group: Washabau *et al.*, 2010). Duodenal mucosa has been a subject of fundamental studies in which characteristics of the duodenal mucosa of dogs were assessed by morphometric and immunohistochemical methods (Janeczko *et al.*, 2008; Waly *et al.*, 2001; German *et al.*, 1999). Such studies described the morphologic and inflammatory changes that indicate the degree of inflammation include: examination of changes in the intestinal villi, determination of intestinal epithelial damage, crypt enlargement, presence of lymphatic vessels and fibrosis, as well as monitoring the presence of intraepithelial lymphocytes (IEL), plasma cells, eosinophils and neutrophil infiltrates in the mucosa (WSAVA International Gastrointestinal Standardization group: Washabau *et al.*, 2010).

Determination of detailed clinical signs of dogs suffering from LPD is very important. By using the clinical activity index: CIBDAI (Canine inflammatory bowel disease activity index) and the CCECAI (Canine Chronic enteropathy clinical activity index) the intensity of the disease based on clinical symptoms can be precisely determined (Allenspach, 2007; Jergins *et al.*, 2003). However, no correlation of these clinical indices with the intensity of morphological changes in the duodenum of dogs with LPD was established.

Clarification of cell populations from the morphological and immunophenotypic aspects would contribute to a better understanding of the pathogenesis of plasma cell-lymphocytic duodenitis in dogs, which when correlated with clinical findings would allow accurate diagnosis and adequate therapy.

MATERIAL AND METHODS

Material: The study involved 60 adult dogs of different breeds and both sexes: 54 dogs with symptoms of diarrhea and vomiting that lasted longer than three weeks and six clinically healthy dogs that served as controls.

Clinical trials have included both general and special examinations of the patient. Based on data obtained from history, hematological and biochemical blood analysis the clinical activity indices were calculated: CIBDAI and CCECAI. Hematologic analysis was performed on an automatic hematology analyzer, and

serum biochemical analysis was performed using a semi-automatic biochemical spectrophotometer and the values of the following parameters were determined: alanine transaminase (ALT), aspartate aminotransferase (AST), alkaline phosphatase (AP), urea, creatinine, total protein, serum albumin and glucose.

Coprological investigation included analysis for the presence of nematodes and protozoal parasites. Microscopic examination of feces was based on qualitative flotation methods.

Radiological studies included special X-ray examination with positive contrast (barium sulfate). Preparation of the patient for examination consisted of one-day fasting, without limiting the intake of fluids and by giving laxatives. The amount of contrast applied was 100 - 200 ml, depending on the size of the animal. For radiographs the apparatus used was SELENOS fourth Conditions for the record: 45-60 kV, 10-25 mAs, FFO-60 – 70 cm. Projections for the record: LL - latero-lateral and as needed VD – ventrobasal dorsal and DV – dorso-ventral projections.

Ultrasound diagnosis was made with prior preparation of the patient which included fasting for 12 to 24 hours before the examination.

Endoscopic examination was performed under general inhalation anesthesia with prior food deprivation 12 to 24 hours and deprivation of water 4 hours before the examination. Following inhalation general anesthesia for endoscopy a STORC endoscope with a video camera was used, which consists of an endoscope (diameter 9 mm), a working channel (diameter 2.2 mm and length 140 mm) and a light source. To perform an endoscopic guided biopsy a special "alligator" biopser was used.

Histopathology: morphological changes are described in the duodenal mucosa (changes in the intestinal villi, degree of damage to the intestinal epithelium, existence of crypt extensions, dilated crypts, presence of lymphatic vessels and fibrosis). The incidence of intraepithelial lymphocytes (IEL), lymphocytes, plasma cells, eosinophils and neutrophil infiltrate in the mucosa was examined, also. Tissue samples were fixed in 10% buffered formalin, and, after standard processing in an automated tissue processor, cast in paraffin blocks. Paraffin sections 3-5 μm thick were stained with hematoxylin and eosin and with Giemsa method for light microscopic examination. Normal tissue sections obtained from three dogs with no evidence of disease were used as controls.

Immunohistochemistry: Three-step indirect immunohistochemical technique was performed. After antigen retrieval and inactivation of endogenous peroxidase, sections were incubated with appropriate primary antibodies diluted in PBS (for the B cell lineage, monoclonal-mouse anti human CD79, DAKO M7051 and for T cell lineage, monoclonal anti human CD3, DAKO A0452). All rinsing procedures and serum dilutions were done in PBS (pH 7.2). The detection kit was LSAB2 System-HRP, Rabbit/mouse (DAKO, K0675). Reactions were visualized by DAB+ (DAKO, K3468) and counterstained with hematoxylin. Sections not treated with the primary antibody were used as negative controls.

For statistical analysis of the results the basic statistical methods used were descriptive statistical parameters (arithmetic mean, standard deviation, standard

error, variation interval and coefficient of variation). In order to test and establish the degree of statistical significance of the difference between tested groups Student's t-test was applied, by which statistically significant differences between individual treatments were estimated. The statistical significance of the differences was reported for levels of significance of 5 and 1%.

Statistical analysis of the results was performed with the help of the statistical package PrismaPad 4.00.

RESULTS

Of the 54 affected dogs, 3 dogs were diagnosed with eosinophilic duodenitis and 5 dogs had a diagnosis of catarrhal duodenitis. The remaining 46 dogs were diagnosed with lymphocytic-plasmacytic duodenitis (LPD). Presented results concern the 46 dogs with diagnosed LPD.

The group of dogs affected by LPD comprised 15 female and 31 male animals, aged from 5 months to 14 years. Ten dogs were mixed breed and 36 dogs were pedigree dogs.

Hematological analysis showed increased values for the number of leukocytes and lymphocytes in all animals. The mean leukocyte count was $19.30 \times 10^9/L$, while the percentage of lymphocytes was 69.48%.

Biochemical parameters were within normal limits except for total protein and serum albumin, which in some animals were below the normal range. A decreased concentration of protein (<50 g/L) was found in 63.04% of tested dogs (29/46). Mean protein concentration was 45.48 g/L. Reduced serum albumin concentration was detected in 71.74% of dogs (33/46). Mean serum albumin concentration was 25.70 g/L. The test results of blood biochemical parameters in dogs with LPD and controls are shown in Table 1.

Table 1. Results of biochemical blood parameters in LPD dogs and control group

		ALT (IU/L)	AST (IU/LL)	AP (IU/LL)	Total protein (g/dL)	Albumin (g/dL)
\bar{X}	LPD dogs	29.87	31.28	87.67	45.48 ^a	25.70 ^a
	Control group	29.83	32.67	83.33	65.83 ^a	32.50 ^a
SD	LPD dogs	11.24	11.07	36.33	5.605	3.379
	Control group	11.58	12.50	34.07	8.134	3.507
SE	LPD dogs	1.657	1.632	5.357	0.8263	0.4982
	Control group	4.729	5.103	13.91	3.321	1.432
CV (%)	LPD dogs	37.63	35.39	41.44	12.32	13.15
	Control group	38.83	38.27	40.88	12.36	10.79
X_{\min}	LPD dogs	12	12	21	37	18
	Control group	12	12	38	55	28
X_{\max}	LPD dogs	49	55	164	56	31
	Control group	42	45	121	76	37

Some letters indicate a statistically significant difference between the LPD affected dogs and the control group for total protein and albumin a, $p > 0.01$

The overall CIBDAI mean was 7.48. CCECAI value coincides with the CIBDAI value, except for the 5 dogs in which the concentration of serum albumin was between 15 and 19.9 g/L. Such a result in these dogs can result in increased CCECAI by 1 point. The overall mean was 7.59 CCECAI.

Ultrasound examination of all dogs with LPD exhibited a wavy appearance of the duodenal wall. The mucosa and submucosa of the intestines was thickened and the lumen dilated. All the layered features of the intestinal wall were preserved. The mucosa was markedly anechogenic and wall thickness in all dogs was between 4-6 mm. In a dog hyperechoic small grain-like fields protruding above the thickened lining of the intestine were seen (bowel wall thickness was 4-6 mm).

Coprology did not revealed presence of parasites in any of the studied dogs.

On X-ray examination of the duodenum in VD and LL projections using positive contrast we found disparity and spasticity of the gut lumen in all specimens, especially in 11 cases where CIBDAI \geq 9. In most cases the changes were described to be bulbar, and the metal shadow boundaries of barium sulfate with the surrounding soft tissue were corrugated, discontinuous and hazy. The surface of the mucosa was deformed due to spasm and edema, and had a marble-like appearance due to barium deposits attached to the hypertrophic mucosal folds. Due to the presence of mucus, blood and desquamated epithelium, downy flocculation (fragmentation) of the contrasting mixture on slimy layer was seen with double contours of the wall of the duodenum. The accumulation of gas in the form of transparent fields, regularly accompanied these inflammatory changes. In addition to morphological, X-ray diagnostics established functional, motor and secretion disorders of the duodenum. They are manifested by hyper peristalsis and rapid passage of contrast to the caudal

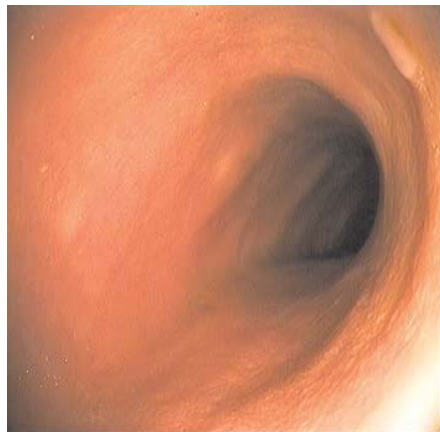

Figure 1. Duodenal mucosa of healthy dogs is smooth, shiny, moist and translucent. Endoscopic view

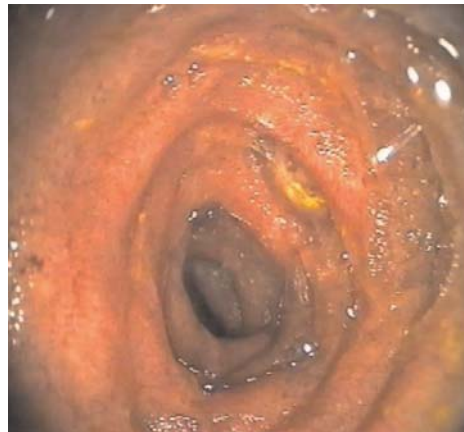

Figure 2. Duodenal mucosa of dogs with LPD is hyperaemic and edematous. Endoscopic view

segments of the small intestine, so that in 11 dogs (CIBDAI ≥ 9) the contrast reached the duodenum within several minutes, instead of 20 to 30 minutes.

During endoscopic examination the duodenal mucosa of healthy dogs was smooth, shiny, moist and translucent (Fig. 1).

However, in 46 dogs with LPD, duodenal wall thickening, hyperemia and edema of the mucosa of the duodenum were recorded (Fig. 2).

During biopsy the tissue bled easily. In 7 dogs (CIBDAI <6) the duodenal mucosa was less hyperemic and only partially edematous. In the remaining 39 dogs (CIBDAI ≥ 6) severe hyperemia and edema of the duodenal mucosa could be observed. On the surface of the mucosa in one dog, small grain-like fields, white in color, sprinkled on the mucosa in a diameter from 2 to 3 mm were clearly observed. Biopsy samples were taken from the changed areas of the duodenum.

Histopathology: Histopathological examination showed the following result: in the *lamina propria* of the duodenum, infiltration of numerous mononuclear cells dominated by lymphocytes and plasma cells was observed in 46 dogs (Fig. 3).

In 31 dogs in the cellular infiltrate there was a predominance of lymphocytes, while plasmacytes were dominant in two dogs. In dogs with lymphocytic duodenitis $5 \leq \text{CIBDAI} \leq 10$, while in both dogs with plasmacytic duodenitis, was CIBDAI 5. Other dogs with lymphocytic-plasmacytic duodenitis have $5 \leq \text{CIBDAI} \leq 11$. Due to the presence of abundant cellular infiltrate composed of lymphocytes and plasma cells the *lamina propria* was greatly emphasized. Plasma cells usually group in the *lamina propria* of the villi. The mucosa of the duodenum in healthy dogs is arranged into finger-like projections called villi with intervening short glands called crypts. Between crypts, there may be 1-2 lymphocytes or plasma cells. In dogs with LPD, crypts are usually separated by 10-20 lymphocytes and plasma cells.

Single cells placed intraepithelially (intraepithelial lymphocytes - IEL) were observed, also. In several dogs eosinophilic and neutrophilic granulocytes were

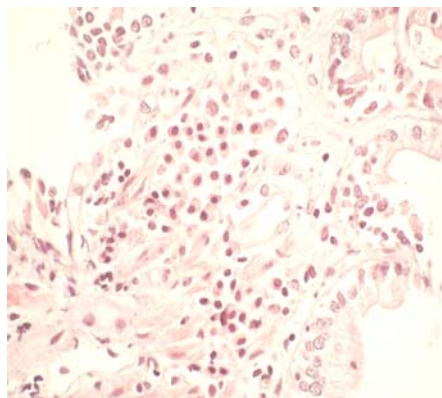


Figure 3. Infiltration of duodenal mucosa with numerous lymphocytes and plasma cells, HE, 200x

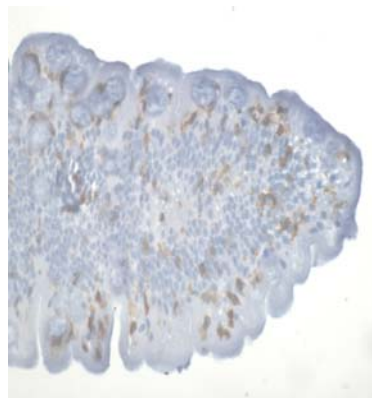


Figure 4. The positive immunohistochemical reaction with a dark brown precipitate in the cell membrane of T lymphocytes, CD3+, LSAB 2, 100

found in small numbers. Villi in most dogs were half shortened, thickened, and some were fused (joined together). In the epithelial cells of the duodenum were present degenerative changes, and in some dogs, desquamation of epithelial cells was found. Most of the intestinal crypts were dilated and irregular in shape and filled with detritus. The *lamina propria* was edematous. In one dog the main lymphatic vessels were enlarged. In this dog during ultrasound examination, small hyperechoic grain fields protruded above the surface of the thickened bowel mucosa while endoscopic mucosal surface disclosed small (2-3mm) grain-like fields, white in color, sprinkled onto the mucosa.

Immunohistochemical methods detected the expression of dominant CD3+ T lymphocytes in the samples of 31 dogs with lymphocytic – plasmacytic duodenitis ($5 \leq \text{CIBDAI} \leq 10$), while two samples were dominated by CD79 + cell phenotype ($\text{CIBDAI} = 5$). The positive immunohistochemical reaction was manifested by a dark brown precipitate in the area of the cell membrane of T lymphocytes (Fig. 4).

The immunohistochemical reaction of B lymphocytes, has a more diffuse character.

DISCUSSION

Chronic enteropathies account for more than half of all disorders of the digestive system in dogs. Inflammatory bowel disease (IBD) is a common name for a chronic enteropathy, which is primarily characterized by inflammation of the lining of the gastrointestinal system and nonspecific clinical symptoms.

This study included dogs with symptoms of diarrhea (46/46) and vomiting (34/46) that lasted longer than three weeks, and were in bad condition (44/46) and with altered temperament (43/46). Carefully were systematized data on behavior, appetite, weight loss, quality and quantity of stools and vomiting, according to the recommendations of the WSAVA (Washabau *et al.*, 2010) in order to calculate and CIBDAI CCECAI. These results are consistent with findings of other authors who followed the parameters required for the study CCECAI index (Garcia-Sancho *et al.*, 2010; Jergens, 2008, Allenspach, 2007; Garcia-Sancho *et al.*, 2007). The overall mean was 7.48 CIBDAI. The obtained CIBDAI values formed three groups of patients: the first group with a mild form of LPD was formed by 7 dogs ($\text{CIBDAI} \leq 5$), another group of 28 dogs has medium intensity LPD, ($6 \leq \text{CIBDAI} \leq 8$) and the third group with significant LPD consisted of 11 dogs ($\text{CIBDAI} \geq 9$). According to morphological findings, were formed also three groups of dogs: 31 dogs with a dominant cell population consisting of T lymphocytes, in 2 cases dominated by plasma cells, while in 13 dogs was established a uniformly mixed infiltrate of lymphocytes and plasma cells. In the mildly affected LPD group were 2 dogs with predominantly plasmacytic infiltrates, 4 dogs with a dominant lymphocytic infiltrate and a dog with lymphocytic-plasmacytic infiltrate. In the medium to strongly affected LPD group were 23 dogs with lymphocytic infiltrate and 5 dogs with lymphocytic-plasmacytic infiltrate. In the group with significant LPD were 4 dogs with predominantly lymphocytic infiltrate, and 7 dogs with lymphocytic-plasmacytic infiltrate. CCECAI value coincides with the value CIBDAI, except for

one dog from Group II and four dogs from Group III, where the concentration of serum albumins was between 15 and 19.9 g/L. Such a result can induce the CCECAI to increase by 1 point. The overall mean was 7.59 CCECAI. Based upon the CCECAI values which describe the strength of enteropathy, we were able to classify patients as follows: mild enteropathy was present in 7 dogs (CCECAI \leq 5), medium intensity enteropathy in 28 dogs ($6 \leq$ CCECAI \leq 8), and severe enteropathy in 10 dogs ($9 \leq$ CCECAI \leq 11) while very severe enteropathy was diagnosed in 1 dog (CCECAI \geq 12). The first three groups of patients are consistent with the division on the basis of CIBDAI values. In the fourth group of very serious enteropathy sufferers the mixed lymphocyte-plasmacytic infiltrate was present.

The results of hematological and biochemical parameters obtained in our studies emphasize the change in value for the number of leukocytes and lymphocytes, which were in all animals above the normal range (mean leukocyte count was $19.30 \times 10^9/L$ while the mean value of lymphocyte count was $6.52 \times 10^9/L$), as well as changes in total protein and serum albumin which in most animals were below the normal range (mean protein concentration was 45.48 g/L while the mean serum albumin concentration of 25.70 g/L). This is consistent with findings of other authors who followed the parameters required for the study of clinical indices (Garcia-Sancho *et al.*, 2010; Lecoinde 2007; Kobayashi *et al.*, 2007).

Knowledge of the basic characteristics of gut mucosal immune system and normal morphology of the duodenum of dogs, is essential for understanding the pathogenesis of LPD in dogs. It is known that the mucosal immune system is highly specialized and protects the mucosal surfaces from the harmful effects of various agents. Local lymphatic tissue cancer (Gut associated lymphoid tissue - GALT), which is an integral component of the lymphoid tissue mucosa (Mucosal associated lymphoid tissue - MALT) represents a significant reservoir of immune cells. Intestinal immune system suppresses the immune response to a greater extent than it is activated, using several mechanisms to protect the host. Some of the mechanisms of protection include a reliable physical barrier, the presence of enzymes in the lumen of the intestine that alter the very nature of the antigen, the presence of specific regulatory T cells and production of immunoglobulin A class (Nandakumar *et al.*, 2009; Sakaguchi *et al.*, 2008; Untersmayr *et al.*, 2006; Mayer, 2003; Nagler-Anderson, 2001; York *et al.*, 1999).

ACKNOWLEDGEMENT:

The research was supported by grant from the Ministry of Science, Project III 46002

Address for correspondence:
Đorđević Milena
Department of Anatomy
Faculty of Veterinary Medicine
University of Belgrade
Bulevar oslobođenja 18
11000 Belgrade, Serbia
E-mail: milenadj@vet.bg.ac.rs

REFERENCES

1. Allenspach K, Wieland B, Grone A, Gaschen F, 2007, Chronic enteropathies in dogs: evaluation of risk factors for negative outcome, *J Vet Intern Med*, 21, 4, 700-8.
2. Craven M, Simpson JW, Ridyard AE, Chandler ML, 2004, Canine inflammatory bowel disease: retrospective analysis of diagnosis and outcome in 80 cases (1995-2002), *Journal of Small Anim Pract*, 45, 336-42.
3. García-Sancho M, Rodríguez-Franco F, Sainz A, Mancho C, Rodríguez A, 2007, Evaluation of clinical, macroscopic, and histopathologic response to treatment in nonhypoproteinemic dogs with lymphocytic-plasmacytic enteritis, *J Vet Intern Med*, 21, 1, 11-7.
4. García-Sancho M, Sainz A, Villaescusa A, Rodríguez A, Rodríguez-Franco F, 2010, White spots on the mucosal surface of the duodenum in dogs with lymphocytic-plasmacytic enteritis, *J Vet Sci*, 12, 2, 165-9.
5. German AJ, Hall EJ, Moore PF, Ringler DJ, Newman W, Day MJ, 1999, Analysis of leucocyte subsets in the canine intestine, *J Comp Path*, 120, 129-45.
6. Janeczko S, Atwater D, Bogel E, Greiter-Wilke A, Gerold A, Baumgart M, et al, 2008, The relationship of mucosal bacteria to duodenal histopathology, cytokine mRNA, and clinical disease activity in cats with inflammatory bowel disease, *Vet Micro*, 128, 178-93.
7. Jergens AE, Schreiner CA, Frank DE, Niyo Y, Ahrens FE, Eckersall PD, et al, 2003, A scoring index for disease activity in canine inflammatory bowel disease, *J Vet Intern Med*, 17, 3, 291-7.
8. Jergens AE, 2008, Inflammatory bowel disease in the dog (IBD), Dog Health by Lowchens, Australia.com
9. Kobayashi S, Ohno K, Uetsuka K, Nakashima K, Setoguchi A, Fujino Y, et al, 2007, Measurement of intestinal mucosal permeability in dogs with lymphocytic-plasmacytic enteritis, *J Vet Med Sci*, 69, 7, 745-9.
10. Lecoindre P, 2006, Chronic inflammatory bowel diseases, etiopathogeny, diagnosis, Communication Bull Acad Vet France, Tome 159-N4.
11. Mayer L, 2003, Mucosal immunity, *Pediatrics*, 111, 1595-600.
12. Nagler-Anderson C, 2001, Strategic defences in the intestinal mucosa, *Nat Rev Immunol*, 1, 59-67.
13. Nandakumar S, Miller CWT, Kumarguru U, 2009, T regulatory cells: an overview and intervention techniques to modulate allergy outcome, *Clin Mol Allerg*, 7, 5-13.
14. Sakaguchi S, Yamaguchi T, Nomura T, Ono M, 2008, Regulatory T cells and immune tolerance, *Cell*, 5, 775-87.
15. Simpson KW, Jergens AE, 2011, Pitfalls and progress in the diagnosis and management of canine inflammatory bowel disease, *Vet Clin North Am Small Anim Pract*, 41, 2, 381-98.
16. Untersmayr E, Jensen-Jarolim E, 2006, Mechanisms of type I food allergy, *Pharmacol Therapeut*, 112, 787-98.
17. Waly N, Gruffydd-Jones TJ, Stokes CR, Day MJ, 2001, The distribution of leucocyte subsets in the small intestine of normal cats, *J Comp Path*, 124, 172-82.
18. Washabau RJ, Day MJ, Willard MD, Hall EJ, Jergens AE, Mansell J, et al, 2010, Endoscopic, biopsy, and histopathologic guidelines for the evaluation of gastrointestinal inflammation in companion animals, *J Vet Intern Med*, 24, 10-26.
19. Whitley NT, Day MJ, 2011, Immunomodulatory drugs and their application to the management of canine immune-mediated disease, *J Small Anim Pract*, 52, 70-85.
20. York IA, Goldberg AL, Mo XY, Rock KL, 1999, Proteolysis and class I major histocompatibility complex antigen presentation, *Immunol Rev*, 172, 49-66.

MORFOLOŠKE, IMUNOFENOTIPSKE I KLINIČKE KARAKTERISTIKE LIMFOCITNO – PLAZMOCITNOG DUODENITISA PASA

ĐORĐEVIĆ MILENA, KRSTIĆ V, KRSTIĆ N, VASILJEVIĆ MAJA, ILIĆ V,
VUČIĆEVIĆ IVANA i ALEKSIĆ-KOVAČEVIĆ SANJA

SADRŽAJ

Najvažnija morfološka karakteristika imunskog odgovora kod limfocitno-plazmocitnog duodenitisa (LPD) pasa je nalaz infiltrata mononuklearnih ćelija krvi u sluzokoži duodenuma. Do danas etiopatogeneza ove bolesti pasa nije u svemu poznata, a nisu poznate ni sve imunofenotipske karakteristike ćelija u infiltratu, koje bi bile značajne za razumevanje etiopatogeneze LPD.

Ispitivanjem je bilo obuhvaćeno ukupno 60 odraslih pasa, različitih rasa i oba pola: 54 psa sa simptomima dijareje i povraćanja koje je trajalo duže od tri nedelje i šest klinički zdravih pasa koji su služili kao kontrola. Urađene su hematološke i biohemijske analize krvi, a zatim je sprovedena radiološka, ultrazvučna i endoskopska dijagnostika. Uzorci mukoze duodenuma, uzeti biopsijom, ispitani su histopatološkim i imunohistohemijskim metodama.

Pri endoskopskom pregledu, kod 46 pasa je zapažen zadebljali zid duodenuma, hiperemičnost i edem sluznice. Mikroskopskim ispitivanjima, na epitelnim ćelijama duodenuma uočene su degenerativne promene, a nekada i deskvacija. Većina crevnih kripti je bila dilatirana, nepravilnog oblika i ispunjena detritusom. Imunohistohemijskim ispitivanjem uzoraka duodenuma kod većine pasa sa LPD uočena je dominacija CD3+T limfocita.